

Spontaneous Splenic Rupture Under Xarelto

Ekkehard Pietsch*, Michaela Nyström and Frank Templin

Department of General Surgery, Johanniter Krankenhaus, Geesthacht, Germany

***Corresponding Author:** Ekkehard Pietsch, Department of General Surgery, Johanniter Krankenhaus, Geesthacht, Germany.

Received: October 19, 2021

Abstract

With the establishment of new oral anticoagulants, the clinician is confronted with bleeding complications that pose a potential threat to the patient that can be life-threatening. We report a case of a spontaneous atraumatic splenic rupture under rivaroxaban in a 76-year-old woman. Her clinical condition started to deteriorate during admission, which resulted in early laparotomy and splenectomy. There are only a few cases in the literature, which cover different treatment options.

Keywords: Rivaroxaban; Xarelto; Splenic Rupture; Spontaneous Splenic Rupture

Introduction

A 76-year-old woman presented to the emergency room with dull and continuous aches in the left upper abdomen of short duration. On examination, tenderness was found under the left ribcage. Ultrasound queried free fluid and suspicious in homogenous fluid patterns in the spleen. A CT scan confirmed a splenic rupture with an avulsion of the capsule. Within 90 minutes of admission, the patient's condition deteriorated resulting in emergency laparotomy with splenectomy.

The Case

A 76-year-old woman presented to the emergency room with dull and continuous aches in the left upper abdomen. They occurred 2 hours prior to admission and were not accompanied by nausea or vomiting. She had been able to open bowels regularly and did not complain of dysuria. Besides, weight-loss, weakness and night sweats could be denied. Her symptoms were rated as 5/10 VAS. Especially in times of Corona, contacts with people who could have been tested positive or typical Covid symptoms were denied.

Her past medical history was significant for atrial fibrillation and hypertension with a CHA2DS2-VASc-score of 4. Her medication consisted of rivaroxaban 20 mg and verapamil 120 mg.

On examination, the patient presented with facial pallor. She appeared well orientated and was a good historian. In bed, she lay still and did not move. The abdomen felt soft and not distended. There was no evidence of inguinal or abdominal wall hernias. She indicated tenderness below the left ribcage but no signs of peritonism. Bowel sounds were present and unremarkable.

An ECG confirmed atrial fibrillation with an irregular ventricular response. Her urine dip stick was normal. The Ultrasound of the abdomen revealed no fluid in the pouches but a small collection in the pelvis of approximately 50 ml. Liver, biliary tract and pancreas appeared within limits. The spleen, however, was normal in size but showed a sickle-like inhomogeneity within the parenchyma. A CT of the

Spontaneous Splenic Rupture Under Xarelto

abdomen followed. It revealed a ruptured spleen with free fluid in the pelvis and the left renal pouch. The full blood count, troponin, CK, CK-MB, creatinine and liver function tests were within normal limits. Her Covid-19 antigen test was negative.

In the course of her investigations and within 90 minutes of admission, the patient's condition deteriorated. She developed tenderness and distension of the abdomen and a drop in her blood pressure indicating active bleeding. The patient was taken to theatre and an emergency laparotomy was conducted. The exploration revealed 2000 ml of blood within the abdominal cavity without any clots. The spleen was completely decapsulated with no signs of a parenchymal defect. A splenectomy was performed. The histological findings showed only an unspecific splenitis without any signs of a previous trauma or other specific pathologies.

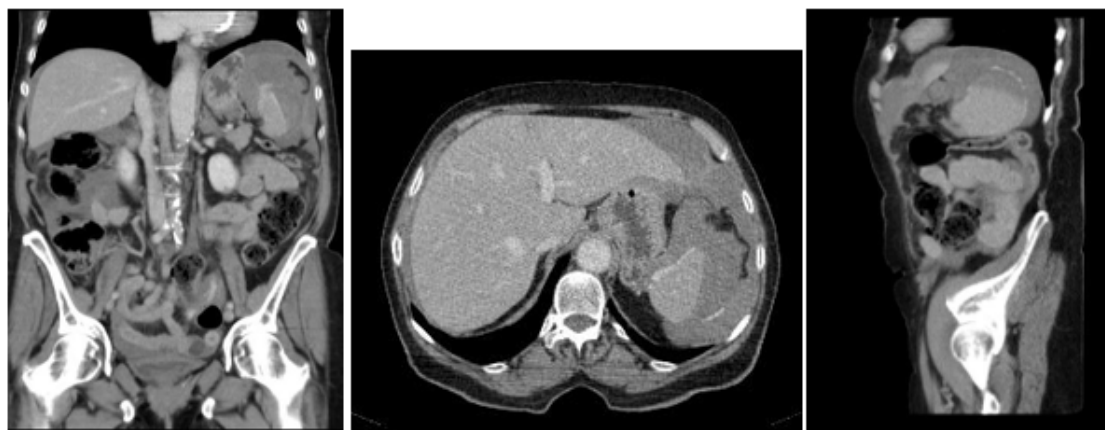


Figure 1: Initial CT abdomen.

Discussion

The aetiology of acute splenic rupture in the most frequent cases is related to trauma. However, there are also atraumatic causes among which six major aetiological groups can be defined. In a review of 865 patients, Renzulli [1] found 7% atraumatic-idiopathic cases and specific pathologies, which consisted of neoplastic (30.3%), infectious (27.3%), inflammatory, non-infectious (20%), mechanical disorders (6.8%), and 9,2% drug- and treatment-related cases. Among drugs, especially anticoagulants have been associated with non-traumatic splenic rupture [2,3]. In patients receiving long-term anticoagulants, they can be lethal as bleeding complications in 9%. Depending on predisposing conditions mortality can rise to 50% after thrombolytic therapy or even 66% after cardiovascular intervention [4].

In the presented case, no other cause except for oral anticoagulation was found. Literature so far finds 5 cases of a spontaneous splenic rupture under rivaroxaban [5-9]. Rivaroxaban is one of the new generation anticoagulant and a direct factor Xa inhibitor. It is used in the prophylaxis of VTE and for the prevention of stroke in atrial fibrillation.

The clinical presentation of the patient with the given symptoms and her past medical history was initially leading into a different direction. Classical symptoms with upper left quadrant pain, distension, nausea or vomiting as well as radiation into the left shoulder as described by Blankenship (1993) were not present. First differentials included cardiac causes. In the emergency department, the patient was prioritized for the internal department before free fluid could be spotted during the Ultrasound examination, for which the general surgeon got involved. The leading diagnosis of a splenic rupture was confirmed through the CT scan.

At this stage, treatment options can include conservative or surgical management if the patient is hemodynamically stable. Conservative options include substitution of blood loss, monitoring or embolisation. In the case of rivaroxaban, its effect, unlike other anticoagulants like dabigatran or apixaban as thrombin inhibitor, can be reversed with prothrombin complex concentrate [10,11] if time allows. In the previously described cases with splenic rupture under rivaroxaban, only Nagaraja (2019) could manage their patient without surgery. After cardioversion for atrial fibrillation, splenic rupture occurred, which was treated with the infusion of prothrombin complex concentrates, 14 units of bloods and 4 units of fresh frozen plasma followed by splenic artery embolisation. The patient's anticoagulation was then stopped. The cases of Gonzva (2014), Yousef (2015) and Naseem (2016) consisted of patients under rivaroxaban and additional aspirin 100 mg in one, amiodarone and amlodipine in the other cases. They all underwent splenectomy. Amin (2015) reported on a case without additional medication that also led to splenectomy. Nagaraja (2019) emphasized the importance of drug-related side effects that increase the interaction with rivaroxaban, i.e. amiodarone [12], amlodipine (Gonzva 2015) and antiplatelet agents. Particular attention should be given in the elderly or patients with renal impairments [13,14].

Our patient's condition deteriorated suggesting active intraabdominal bleeding. In this situation when patients become hemodynamically instable, surgery becomes mandatory. Renzulli (2009) confirmed in his review that treatment of atraumatic splenic rupture usually results in total splenectomy (84.1%) rather than organ-preserving surgery (1.2%) or conservative management (14.7). After 6 cases with atraumatic bleeding of the spleen under rivaroxaban, it can be confirmed that the majority of bleeding complications will result in splenectomy.

Conclusion

Bleeding complications should be considered in patients with abdominal symptoms and oral anticoagulation. It would therefore be advisable to include an abdominal ultrasound in patients with left-sided chest or upper abdominal pain in the routine investigation. This applies especially in patients with a cardiac history, after intervention or on long-term anticoagulation but unremarkable findings.

Bibliography

1. Renzulli P, *et al.* "Systematic review of atraumatic splenic rupture". *British Journal of Surgery* 96.10 (2009): 1114-1121.
2. Blankenship JC and Indeck M. "Spontaneous splenic rupture complicating anticoagulant or thrombolytic therapy". *The American Journal of Medicine* 94.4 (1993): 433-437.
3. De Kubber MM, *et al.* "Non-traumatic splenic rupture in a patient on oral anticoagulation". *The International Journal of Emergency Medicine* 6.1 (2013): 16.
4. Gündes E, *et al.* "Spontaneous splenic rupture related to anticoagulant and antiaggregant treatment". *Gastroenterology Review* 14.2 (2019): 152-156.
5. Gonzva J, *et al.* "Spontaneous splenic rupture in a patient treated with rivaroxaban". *American Journal of Emergency Medicine* 32 (2014): 950.
6. Yousef AH, *et al.* "Rivaroxaban Causing Spontaneous Splenic Rupture, in C52. Illustrative disease presentations in critical care I". American Thoracic Society (2015): A4632.
7. Amin A, *et al.* "Hemorrhagic Shock from Spontaneous Splenic Rupture Requiring Open Splenectomy in a Patient Taking Rivaroxaban". *The American Surgeon* 82 (2016): E54-55.
8. Naseem Z, *et al.* "Spontaneous splenic rupture secondary to rivaroxaban: Rare but raising". *Indian Journal of Sleep Medicine* 2 (2016): 134-136.

9. Nagaraja V, *et al.* "Spontaneous splenic rupture due to rivaroxaban". *BMJ Case Reports - A Journal for Medical Case Reports* (2018): 1-3.
10. Eerenberg ES, *et al.* "Reversal of Rivaroxaban and Dabigatran by Prothrombin Complex Concentrate - A Randomized, Placebo-Controlled, Crossover Study in Healthy Subjects" (2011).
11. Giffard-Quillon L, *et al.* "Reversal of rivaroxaban anticoagulant effect by prothrombin complex concentrates: which dose is sufficient to restore normal thrombin generation?" *Thrombosis Journal* 18 (2020): 15.
12. Hellwig T and Gulseth M. "Pharmacokinetic and pharmacodynamic drug interactions with new oral anticoagulants: what do they mean for patients with atrial fibrillation?" *Annals of Pharmacotherapy* 47 (2013): 1478-1487.
13. Pisters R, *et al.* "A novel user-friendly score (HAS-BLED) to assess 1-year risk of major bleeding in patients with atrial fibrillation: the Euro Heart Survey". *Chest* 138 (2010): 1093-1100.
14. Kobayashi N, *et al.* "A new scoring system (DAIGA) for predicting bleeding complications in atrial fibrillation patients after drug eluting stent implantation with triple antithrombotic therapy". *International Journal of Cardiology* 223 (2016): 985-991.

Volume 8 Issue 12 December 2021

©All rights reserved by Ekkehard Pietsch, *et al.*