

The Medicolegal Aspect of the Scapholunate Injury

Ekkehard Pietsch*

Orthopaedic and General Surgeon, The-Expert-Witness.de, Hamburg, Germany

***Corresponding Author:** Ekkehard Pietsch, Orthopaedic and General Surgeon, The-Expert-Witness.de, Hamburg, Germany.

Received: February 16, 2016; **Published:** May 14, 2016.

Abstract

The medico legal expert can be confronted with persisting symptoms after a minor injury to the wrist. In this context, injuries to the scapholunate (SL) ligament should be considered. Its incidence is higher than expected and the impact is enormous if it remains undetected and untreated.

Selective sectioning studies have established that the SL ligament is the primary stabilizer in the carpal row and stabilizes the scaphoid and lunate throughout the motion cycles. The ligament can be divided both anatomically and histologically into three parts: dorsal, intermediary and volar. The volar section contains obliquely oriented collagen fascicles. With a tensile strength of 150 N, it is responsible for controlling rotational motion. The volar section is highly innervated and believed to have a major proprioceptive role. The intermediate section of the ligament is the weakest segment with a maximum tensile strength of only 25-50 N. This section consists of fibro cartilaginous tissue completely devoid of neurovascular bundles. Due to its poor strength and low blood supply, it is prone to degenerative tears as well as avulsion off the scaphoid. The dorsal component, in contrast, is the strongest part with a tensile strength of 300 N. It primarily controls flexion and extension. The edges extend into the radiocarpal articular capsule dorsally, the scaphotriquetral and dorsal intercarpal ligaments posteriorly and the intermediate portion of the ligament proximally.

Keywords: *Scapholunate Injury; SL ligament; Neurovascular bundles; SLAC; Garcia-Elias20*

Introduction

Injuries show two characteristics. Firstly, as the ligament has no blood supply, tears usually show a poor healing potential. Secondly, a torn ligament fails to stabilise the proximal carpal row. The ligament acts like the keystone in a roman door arch. Once torn, the proximal carpal bones shift apart and let the distal carpal bones penetrate into the gap. This scapholunate advanced collapse is called SLAC and results in poor wrist function and disability.

Causality

The expert has to relate to the mechanism of the accident to clarify causality of the injury. The requirement to cause damage to the SL ligament is a fall onto the hyper extended wrist or a sudden twist with an abrupt stop. Many injuries are overlooked, as the main concern of the physician is a fracture to the radius or the carpal bones. X-rays may demonstrate a bony lesion but can miss the SL disruption.

There is a high co-incidence of SL-injuries and wrist fractures. It has been increasingly documented with the upcoming wrist arthroscopy. It can already be found in association with type AO, A2 and type AO, A3 radius fractures. The trauma force is "used" to break the distal radius and subsequently, due to carpal supination, to disrupt the SL ligament.

In type B1 fractures, SL disruption results from an avulsion fracture of the radial styloid process due to ulnar deviation of the wrist. Pilny [1] found that immediately after fracture reduction, already 56% of the cases showed SL instability in their radiographs. After 6 weeks, the number increased to 81%. Schadel-Hopfner [2] found a high co-incidence in sagittal fracture extensions into the distal radius.

Not only radius fractures can coincide with SL injury. Jorgsholm [3] observed a coincidence of scaphoid fractures and intrinsic ligament injuries in 34 of 41 wrists. In 29 cases, the scapholunate ligament was injured, with complete rupture occurring in 10 wrists.

Strobel [4] also found a coincidence of SL injuries and scapholunate dissociations.

Apart from traumatic causes, the expert needs to take into account that degenerative changes and lesions can occur in connection with rheumatoid arthritis, gout or chondrocalcinosis.

Symptoms

Clinically, an isolated SL injury presents as a painful and swollen wrist. The swelling can be localised and can impress as a lump over the dorsum of the wrist before it dissolves in the days after injury.

There are two scenarios that need to be considered: Firstly, the initial symptoms can be short-lasting and improve after days of the accident. At that stage, the majority of injuries go undetected or patients believe they simply suffered a sprain.

In this group, a swelling over the dorsum of the wrist can re-occur after years, usually after a second minor trauma. It can be misinterpreted as ganglion. X-rays can show an advanced collapse. In this situation, the last trauma should not be regarded as cause of the X-ray findings.

Secondly, the patient typically continues complaining of symptoms on weight-bearing activities for weeks and months after the accident. Problems occur with repetitive work, e.g., using a PC mouse, or symptoms on lifting and turning or tasks that require good grip strength. Sometimes, the patient describes an audible click on movements with the wrist.

Examination

The clinical examination can reveal point tenderness over the proximal carpal row with tenderness on passive mobilisation of the lunate against the scaphoid (Balottement Test). Radial and ulnar deviation in a flexed position of the wrist is described as painful. The Kirk-Watson Test reveals the typical clicking in the wrist joint once complete instability has occurred.

Diagnosis

The medical expert usually examines the Client within 12 months following an involvement in an accident or even later. Motorcycle injuries or falls in association with persisting symptoms may raise first suspicion in connection with a painful mobilisation of the scaphoid against the lunate.

The mechanism of the injury and a reported normal initial X-ray can be indicative for a missed soft tissue injury. The expert now needs to decide on the extent of investigations to establish the diagnosis.

On standard post accident X-rays, suspicion should be raised in fractures of the radius in general and in sagittal intra articular distal radial fractures with a fracture line pointing at the SL interval in particular.

The most noticeable sign is the widening of the scapholunate gap on PA and PA grip radiographs. However, obtaining a PA view that clearly shows the scapholunate gap without some bony overlap can be difficult. Findings should always be compared side-to-side [5].

Kindynis [6] suggested angling the x-ray tube to obtain a clearer view of the scapholunate joint and to measure the space at the level of the mid portion of the flat ulnar facet of the scaphoid.

The amount of gap that is diagnostic of scapholunate dissociation is not clearly agreed upon. Many authors define the gap to be pathologic varying from 2 mm to 5 mm using plain radiographs [7-11]. Cautilli and Wehbe [12] measured the gap on 100 normal radiographs and found a mean distance of 3.7 mm (range, 2.5-5mm). They suggested that a scapho-lunate distance of up to 5mm is not necessarily indicative of carpal instability. None of these studies described the measurement method in detail.

However, on X-rays with a queried widening of the SL distance or X-rays, which fulfill the criteria of a high likelihood of SL involvement but no SL widening additional radiographs, such as grip views with a maximum ulnar deviation, help diagnose dynamic instability with a widening of the SL distance.

There are several further signs to determine scapholunate dissociation. There can be a tilt of the lunate into a DISI position, a scapholunate angle >60° or the disruption of the proximal carpal row between scaphoid and lunate.

Bong [13] described an alternative measurement with fluoroscopy. It was found that a 2 mm scapholunate gap appeared the best cut-off point for the fluoroscopic diagnosis in high-grade instability with the wrist in ulnar or neutral deviation.

Given the wide range, comparing the injured wrist with the contra lateral uninjured wrist is crucial before scapholunate dissociation is diagnosed. MRI scans can help to identify the lesion but do not necessarily indicate if it is a static or dynamic lesion. Arthroscopy is despite MRI still the gold standard for the diagnosis, as it allows for direct visualization and assessment of the ligament fibres, which in turn has spawned a number of open and arthroscopic repair methods.

Prognosis

Tears can lead to scapholunate instability and as a result, osteoarthritis of the wrist through the specific SLAC pattern [14,15]. It involves first arthritic lesions at the radial styloid and progress involving the scaphoid fossa. The onset of arthritic lesions occurs rapidly and can become soon detectable on X-rays [16]. It is estimated that this process starts already within weeks after trauma [17] and can result in a complete collapse of the carpal row after 10 to 20 years [18].

After 36 months without further treatment and applying the Wrightington classification, only 14% of Pilny’s patients were free from SLAC, 43% presented with stage I SLAC, 29% with stage IIa SLAC and 14% with stage IIb SLAC. The arthroscopic examination, in contrast, is likely to reveal an even higher and sooner extent of damage. SLAC signs in all patients present as stage I, 29% stage IIa, 42% and stage IIb, 29%.

The most common pattern (57%) is arthritis between the scaphoid, lunate, and radius; 27% of cases occurred between the scaphoid, trapezium, and trapezoid; a combination of these two patterns occurred in 15% [14].

In patients that undergo surgical treatment, the prognosis changes for the better. In 94% of the patients, no signs of SLAC could be found in Pilny’s patients (2010). Only 6% had stage IIa SLAC due to infectious complications.

Bearing the devastating development in mind, it is recommended to treat acute SL injuries surgically rather than with conservative means. The best outcomes of treatment are obtained with treatment in the acute phase or in the first two months after the lesion, especially with partial tears [19].

Classification according Garcia-Elias [20] and treatment options:

Grade I	partial (suture possible)
Grade II	complete (suture possible)
Grade III	complete, scaphoid on stress views without tilt (suture not possible, tenodesis, bone-lig-bone repair)
Grade IV	complete, scaphoid subluxed (as Grade III)
Grade V	complete, scaphoid dislocated (STT arthrodesis or denervation and proximal reconstruction of the wrist bones)
Grade VI	complete, scaphoid displaced on normal XR, SLAC (4-corner fusion with scaphoidectomy)

In chronic injuries, the presence of static malignant usually leads to inferior outcomes. Once there is cartilage loss, the surgeon only has salvage procedures to choose from, tailored to the degree of arthritis.

Pappou [22] described a loss of motion to 60-80 % of the contralateral side. Grip strength averaged 65-90 %.

Deshmukh [23] published a prospective study on 44 cases of SL dissociations treated by Blatt's capsulodesis. Wrist extension was restricted from 60° to 38° (36.7% loss) compared with the unaffected side, flexion reduced from 71° to 40° (43.7%), radial deviation from 17° to 4° (76.5%) and ulnar deviation from 16° to 13° (50%). Post-operative grip strength reached only 75.1% of the unaffected side in their series. Pain relief measured by the Visual Analogue Scale (VAS) improved from 7.9 pre-operatively to 4.1 post-operatively, but only 21 patients (47.7%) had good or excellent pain relief, while 52.3% had only fair to poor relief.

Moran [24] compared a modified Brunelli technique to Berger capsulodesis. 30% loss of motion between the pre and post-operative values was noted in the tenodesis group and 27% loss in the capsulodesis group. Decrease of flexion-extension arc of motion was statistically significant in both groups. There was no difference in the grip strength between the two groups.

Links (2008) [25] compared the Brunelli technique with the four-bone-weave technique in 44 patients and showed better overall results than the four-bone-weave technique. Weiss [26] noted loss of wrist motion, improved grip strength and good satisfaction in 14 patients with a bone-retinaculum-bone technique. All of these techniques result in significant wrist stiffness and eventually lead to arthritic changes.

It is also of note that results after surgery need not remain stable. In a study by Pomerance (2006) [27], for patients followed up for an average of 66 months after surgery, the results, clinically and radiographically, appeared to deteriorate in those who place high demands on the wrists on a daily basis. It was opined that the relevance of a persisting gap after surgery remains unclear.

The Case

A 36-year-old motorcyclist came off his motorbike and sustained a fall onto the wrist. First X-rays demonstrate an intra articular distal radius fracture (AO 23C1) with typical extension of the fracture into the SL joint.

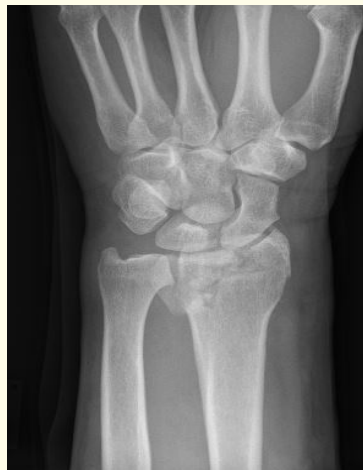

Image 1: After Trauma.

The injury was identified and addressed with a reconstruction and suture anchors. A temporary K-wire fixation was applied to support the reconstructed ligament.

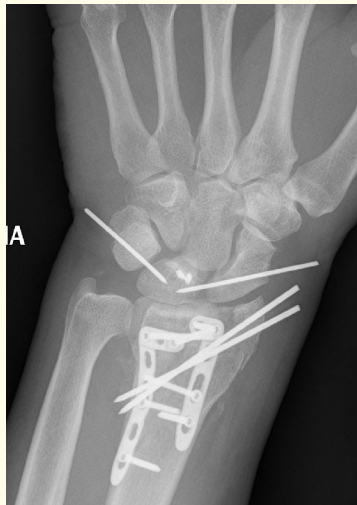

Image 2: Post surgery.

18 months after the trauma, the follow-up shows a wide gap indicating SL instability.

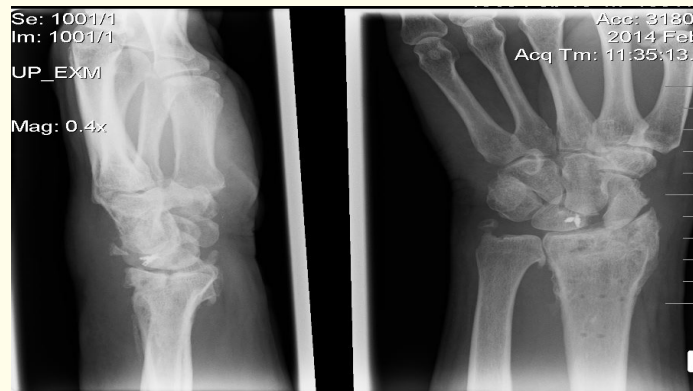


Image 3: 18 months after trauma.

The case shows the progression of SL injury despite surgical intervention. The Client is left with an impaired wrist function and an inability to hold heavy item in his hand.

Bibliography

1. Pilny J., *et al.* "Scapholunate Instability of the Wrist Following Distal Radius Fracture". *Acta Chirurgiae orthopaedicae et Traumatologiae cechoslovaca* 74.1 (2007): 55-58.
2. Schadel-Hopfner M., *et al.* "Arthroscopic Diagnosis of Concomitant Scapholunate Ligament Injuries in Fractures of the Distal Radius". *Handchir Mikrochir Plast Chir* 33.4 (2001): 229-233.
3. Jorgsholm P., *et al.* "The Incidence of Intrinsic and Extrinsic Ligament Injuries in Scaphoid Waist Fractures". *Journal of Hand Surgery American* 35.3 (2010): 368-374.

4. Strobel U., *et al.* "Vergleich Der Funktionellen Resultate Mit MRT-Befunden Nach Operativer Versorgung Von Transskaphoidalen Perilunaren Luxationsfrakturen: Die Rolle Von Skapholunaren Bandlasionen". *Handchir Mikrochir Plast Chir* 46 (2014): 169-176.
5. Pliefke J., *et al.* "Diagnostic Accuracy of Plain Radiographs and Cineradiography in Diagnosing Traumatic Scapholunate Dissociation". *Skeletal Radiology* 37.2 (2008):139-145.
6. Kindynis P., *et al.* "Demonstration of the Scapholunate Space with Radiography". *Radiology* 175.1 (1990): 278-280.
7. Linscheid RL., *et al.* "Traumatic Instability of the Wrist: Diagnosis, Classification and Patho Mechanics". *Journal of Bone and Joint Surgery American* 54.8 (1972): 1612-1632.
8. Linscheid RL. "Scapholunate Ligamentous Instabilities (Dissociations, Subdislocations, Dislocations)". *Ann Chir Main* 3.4 (1984): 323-330.
9. Kindynis P., *et al.* "Demonstration of the Scapholunate Space with Radiography". *Radiology* 175.1 (1990): 278-280.
10. Moneim MS. "The Tangential Postero Anterior Radiograph to Demonstrate Scapholunate Dissociation". *The Journal of bone and joint surgery* 63.8 (1981): 1324-1326.
11. Bednar JM and Osterman AL. "Carpal Instability: Evaluation and Treatment". *The Journal of the American Academy of Orthopaedic Surgeons* 1.1 (1993): 10-17.
12. Cautilli GP and Wehbe MA. "Scapho-Lunate Distance and Cortical Ring Sign". *The Journal of Hand Surgery American* 16.3 (1991): 501-503.
13. Bong Cheol Kwon and Goo Hyun Baek. "Fluoroscopic Diagnosis of Scapholunate Inter osseous Ligament Injuries in Distal Radius Fractures". *Clinical Orthopaedics and Related Research* 466.4 (2008): 969-976.
14. Watson HK and Ballet FL. "The SLAC Wrist: Scapholunate Advanced Collapse Pattern of Degenerative Arthritis". *The Journal of Hand Surgery American* 9.3 (1984): 358-365.
15. Watson HK., *et al.* "The Natural Progression of Scaphoid Instability". *Hand Clinics* 13.1 (1997): 39-49.
16. Pilny J., *et al.* "Arthritis Development Following Untreated Scapholunate Instability of the Wrist". *Acta Chirurgiae Orthopaedicae et Traumatologiae cechoslovaca* 77.2 (2010): 131-133.
17. Papaloizos M. "Scapholunate Lesions and Instabilities-How to Recognize and Treat them"? *Revue Medicale Suisse* 11.477 (2015): 1251-1256.
18. KJ Prommersberger., *et al.* "Die Skapholunare Bandverletzung". *Unfallchirurg* 117(2014): 723-739.
19. Geissler W B Haley T. "Arthroscopy Management of Scapho- Lunate Instability". *Atlas of Hand Clinics* 274 (2001): 6253-6274.
20. Garcia-Elias M., *et al.* "Three-Ligament Tenodesis for the Treatment of Scapholunate Dissociation: Indications and Surgical Technique". *The Journal of Hand Surgery American* 31.1(2006): 125-134.
21. Zarkadas PC., *et al.* "A Survey of the Surgical Management of Acute and Chronic Scapholunate Instability". *The Journal of Hand Surgery American* 29.5 (2004): 848-857.
22. Pappou IP., *et al.* "Scapholunate Ligament Injuries: A Review of Current Concepts". *Hand (N Y)* 8.2 (2013): 146-156.
23. Deshmukh S C., *et al.* "Blatt's Capsulodesis for Chronic Scapholunate Dissociation". *The Journal of Hand Surgery* 24.2 (1999): 215-220.

24. Moran S L., *et al.* "Outcomes of Dorsal Capsulodesis and Tenodesis for Treatment of Scapholunate Instability". *The Journal of Hand Surgery American* 31.9 (2006): 1438-1446.
25. Links AC., *et al.* "Scapholunate Inter Osseous Ligament Reconstruction: Results with a Modified Brunelli Technique Versus Four-Bone Weave". *The Journal of hand surgery American* 33.6 (2008): 850-856.
26. Weiss AP. "Scapholunate Ligament Reconstruction Using a Bone-Retinaculum-Bone Autograft". *The Journal of Hand Surgery American* 23.2 (1998): 205-215.
27. Pomerance JL. "Outcome After Repair of the Scapholunate Inter Osseous Ligament and Dorsal Capsulodesis for Dynamic Scapholunate Instability Due to Trauma". *The Journal of Hand Surgery American* 31.8 (2006): 1380-1386.

Volume 3 Issue 3 May 2016

© All rights reserved by Ekkehard Pietsch